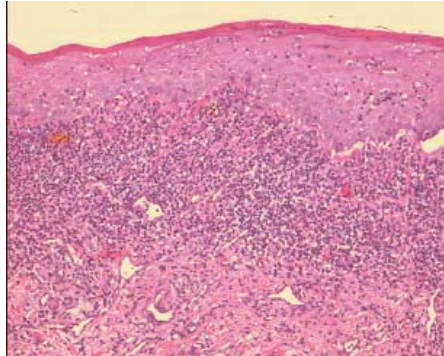
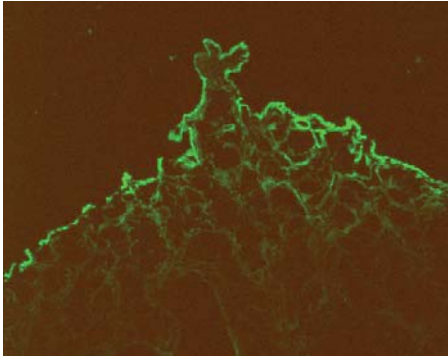


Patient Name		Date of Birth	Sex	Report to:
Patient, Sample		1/1/1970	M	Sample Physician, MD 123 Anyplace Street Anywhere, OR 97213
Path Number	Report	Recvd Date	Collect	
CT09-10002	1/2/2010	1/1/2010	1/1/2010	
<b>Specimen:</b> A. Lower Inner Lip B. Lower Inner Lip Perilesional				

**Gross:** A. One skin punch frozen for dif studies.  
 B. 8x3.5x1mm skin shave, sectioned and submitted entirely in one cassette.  
 Gross examination performed at Curtis T. Thompson M.D. and Associates Laboratory,  
 12254 SW Garden Place, Tigard, OR 97224

**Microscopic:**



A. Direct Immunofluorescence: IgG: Negative. IgM: Negative. IgA: Negative. C3: Trace granular deposition at the dermal/epidermal junction. Fibrinogen: 3+ nonspecific perivascular and interstitial deposition.

B. Sections show a lichenoid infiltrate of lymphocytes, associated with squamotization of the basalis, jagged rete and singly necrotic keratinocytes.

**Diagnosis:**

**A. ORAL CAVITY, LOWER INNER LIP, BIOPSY:  
 NEGATIVE DIRECT IMMUNOFLUORESCENCE STUDY.**

**B. ORAL CAVITY, LOWER INNER LIP, BIOPSY:  
 LICHEN PLANUS.**

**COMMENT:** There is no evidence of an immunobullous disease or vasculitis. Testing was performed with an appropriate positive control for each antibody.

Curtis T. Thompson, MD  
 Board Certified in Dermatopathology  
 Electronically signed by Curtis T. Thompson, M.D. on January 2, 2010 11:50am